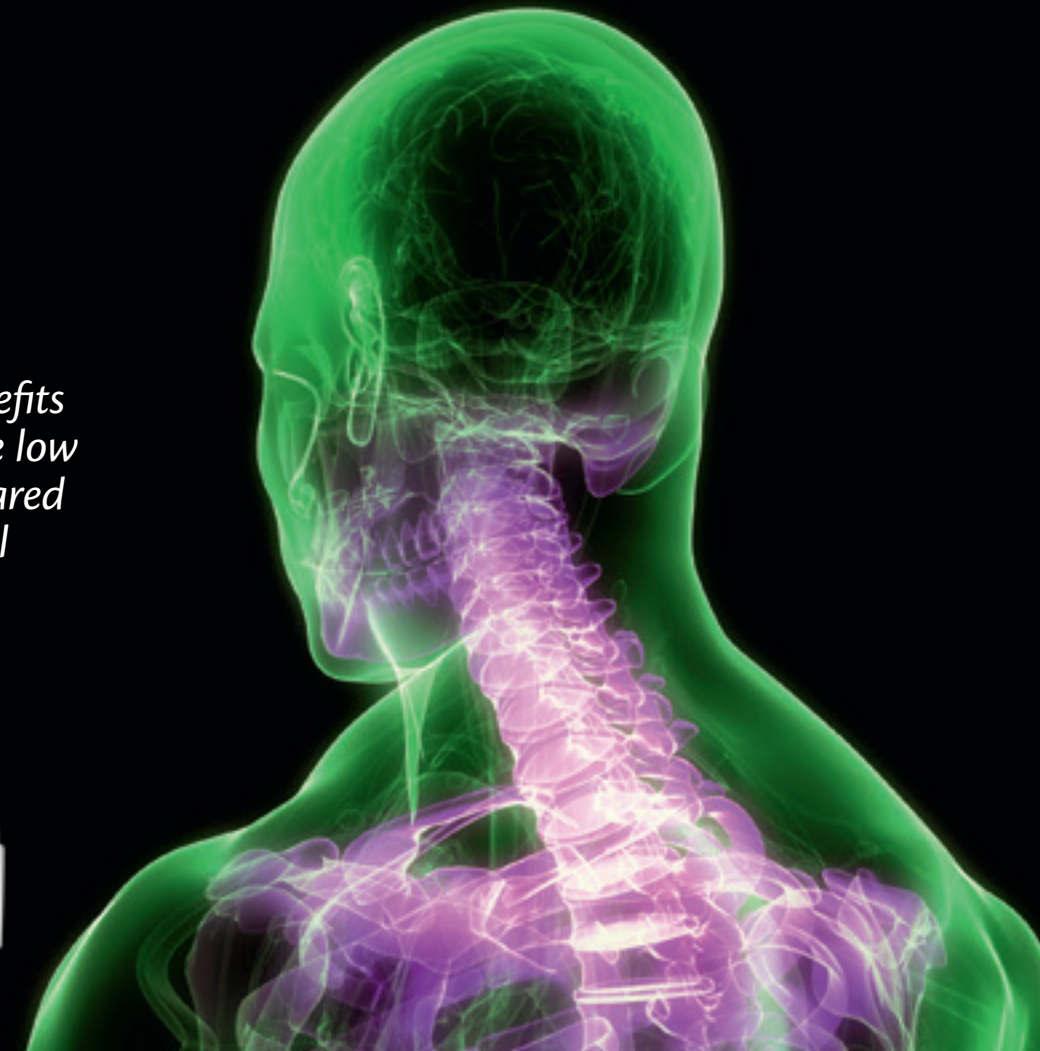
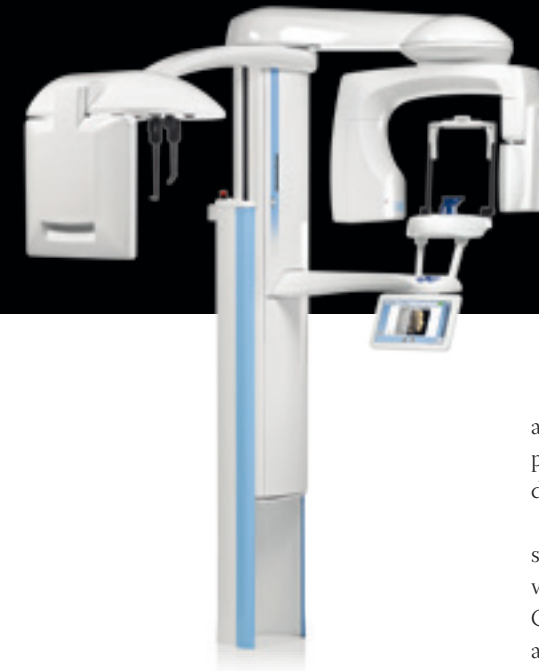

Planmeca's CBCT device also generates crisp images of the anatomy of the upper neck

Physiatrist **Seppo Villanen** (right) and radiologist **Raija Mikkonen**.



One of the many benefits of CBCT imaging is the low radiation dose compared to e.g. a traditional CT scan.

COPY HANNA KORLIN IMAGES JUHA KIENANEN

Two years ago, Seppo Villanen, a Finnish physiatrist specialised in pain management, visited Planmeca's stand at the Finnish Medical Convention and saw a CBCT image of a patient with an obvious sequela of a fracture in the neck area. This gave him the idea of using Planmeca's 3D imaging device for imaging patients with neck problems. The idea turned out to be a success, and nearly 30 patients have now been imaged in cooperation with Pantomo Oy, a company offering dental X-ray imaging services.

Seppo Villanen has his practice at medical center Mehiläinen in the Helsinki Metropolitan Area. The patients he has referred for a CBCT (*cone beam computed tomography*) examination have mostly been patients suffering from pain in the upper neck. "During a routine MRI scan of the neck, the upper neck is usually left outside the image, since the scan acquires transverse slices from the C3 vertebra downwards. What's more, a regular X-ray examination of the neck is routinely performed in a manner that also leaves the upper neck outside the image. CBCT imaging, on the other hand, covers the entire upper neck, from the base of the skull to the C4 vertebra, which is precisely the area that is often missing from routine studies."

Villanen's neck patients are referred to Oral and Maxillofacial Radiology Center Pantomo Oy for imaging with **Planmeca ProMax^{3D}**, and the images are interpreted by radiologist **Raija Mikkonen** at medical center Terveystalo. "We have cooperated with Raija for years," says Villanen.

In most cases, CBCT imaging is done to support MRI imaging, since the methods complement each other. In some cases, however, a CBCT scan is all that is needed: "It

does not provide an insight to soft tissues, but if the image is sufficient to provide an answer to the current question, other methods are not needed."

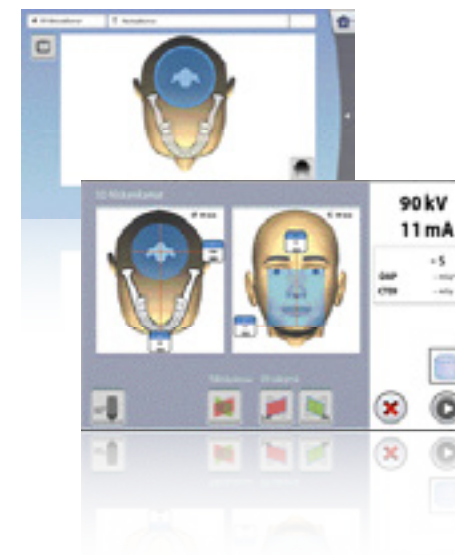Conversely, bony structures do not show up well in MRI images, and small bones can be easily confused with scar tissue. "In a CBCT image, even small changes in the bone are plainly visible," describes Mikkonen.

Thin slices, low radiation doses and a natural head position

One of the many benefits of CBCT imaging is the low radiation dose compared to a traditional CT scan. Moreover, the method produces very thin slices, down to 0.16 mm. In hospitals, CT scans for traumas are usually performed with a slice thickness of 2 mm, and MRI scans are sometimes performed with a slice thickness of up to 5 mm.

"The thinner the slice, the more reliable it is when you are studying small things," says Villanen. "Thin slices have better resolution and afford better measurements. A 2 mm slice does reveal large fractures, but small avulsion fractures might remain undetected."

Furthermore, a CBCT scan can be post-processed to include all required slice thicknesses. "They can also be acquired in



a high resolution CT scan, but that would produce an even higher radiation dose", describes Mikkonen.

Also the patient position is better in a CBCT scan than in a CT scan. A CT scan is acquired with the patient lying down, whereas in a CBCT scan, the patient is sitting up, allowing a more natural head position. "In a lying position, the load experienced by the head is not completely natural. All in all, radiologists should make more use of functional imaging, so that patients could be imaged in their normal working positions, for example."

Fast imaging increases patient comfort

From the patient's perspective, a CBCT scan is quite pleasant – in addition to the low radiation dose, the procedure is quick. A regular MRI scan takes about 20 to 30 minutes, and a functional MRI scan up to two hours, but a CBCT scan is complete in less than a minute.

"Many patients have been surprised at the brevity of the scan," says **Mika Mattila**, specialist in oral and maxillofacial radiology, who is in charge for imaging the neck patients referred to Pantomo Oy by Villanen. "Planmeca's device has a handy cervical spine

program that sets the device automatically to the right position. The only difference in patient positioning, compared to dental patients, is that the head of neck patients must be turned with extreme caution."

The open patient positioning also pleases people with claustrophobia. "Some patients may be very relieved of not having to go into a tube for a scan."

CBCT images of trauma patients

Some of Villanen's CBCT patients have sustained a neck or head injury in an accident: car accident, horse riding accident, a fall, or by a heavy object falling on their head at a construction site. The patients range from 17 to 80 years of age, and the majority of them are women.

"Research shows that all other things being equal, women are more prone to injuries in a car crash than men. The head position is crucial in a crash, and women often make the mistake of first turning their head to see if the children at the back seat are okay. You should not look back, but protect yourself," says Villanen.

Villanen and Mikkonen state that the upper neck is a relatively new area of interest in imaging and medicine. "The upper neck

Mika Mattila, specialist in oral and maxillofacial radiology at Pantomo Oy uses **Planmeca ProMax® 3D** to scan the patients referred to him by Seppo Villanen.



Comparison table

	CT scan	MRI Scan	CBCT Scan
Imaging position	Lying down	Lying down	Sitting
Speed	Relatively quick	Slow	Quick
Radiation	Large dose	No radiation	Small dose
Area of image	Configurable	Configurable	Small (C0–C4)
Functional examinations	Possible	Possible	Possible, not yet tested
Slice thickness	1 mm	2 mm	0,16 mm
Artefacts	Teeth, metal	Metal, movement	Fast scanning, teeth do not disturb the image quality

has been somewhat of a no-man's land, even though it is one of the most mobile joint systems in the body. A neuroradiologist examines the brain, while a radiologist usually examines the area below the C3 vertebra. Treatment of a neck injury patient is a challenging multidisciplinary effort that requires a clinician, a physiotherapist and a radiologist. If a brain or spinal injury is also suspected, the team needs a neurologist and a neuropsychologist as well."

A CBCT scan is an economical imaging method of which many insurance companies have agreed to cover the costs, describes Villanen.

A new standard of resolution

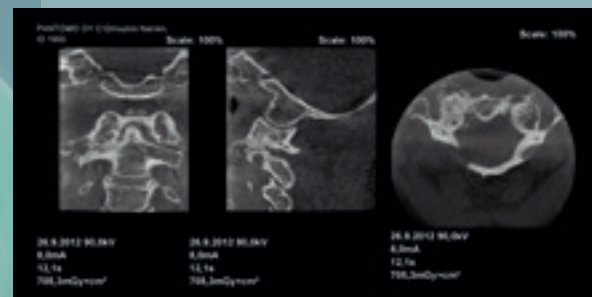
CBCT images are also useful in examining osteoporosis and degenerative changes, since thin slices provide an accurate insight into bone structure. "Compared to the resolution of CT images, CBCT images are on a whole new level", states Villanen.

The **Planmeca Romexis®** software suite is an effective working tool for the radiologists: "The software is fast, visual and easy to use, and various measurements and scrollings work well. It is also a very visual tool in the training of physicians and physiotherapists."

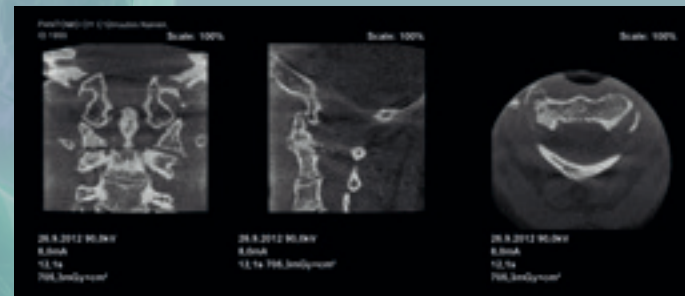
Pantomo too is very happy about this cooperation that has been going on for a few years now. What started as a pilot experiment now provides genuine benefits. "It is great to discover new applications for this imaging method, since we can now obtain additional information and examine the cause of a patient's problems", says Mattila.

Patient Case

A 58-year-old woman, generally healthy. During the past two years, her neck has become so sore and stiff that she can no longer turn her head. Dizziness spells. A lot of soreness on the right side, at the vertebral level C1/C2. No inflammatory arthritis found.



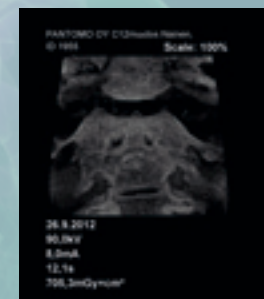
Picture 1. Marked loss of height at the right atlanto-axial joint (C1–C2). Calcification and small bone cysts present in the bone under the articular surface. The structure of the bone is clearly visible.



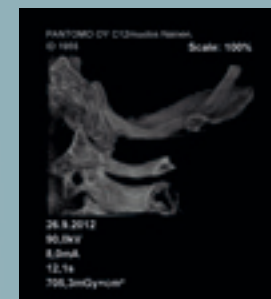Picture 2. Marked loss of height and osteophyte formation at the right atlanto-axial joint. A cyst under the articular surface on the side of the C2 vertebra.

Indications for a CBCT Scan of the neck area

- Determining the bony anatomy of the upper neck on levels C0–C4 (not indicated for imaging ligaments)
- Fractures of the upper neck
- Avulsion injuries of the upper neck
- Differential diagnostics of arthrosis/rheumatoid arthritis of the upper neck
- Subluxation and abnormal rotation positions of the upper neck
- Internal structure of bone



Picture 3a. The dens has moved to the left in relation to the C1 vertebra. Osteophytes in the atlanto-axial joint.



Picture 3b. A large anterior osteophyte in the atlanto-axial joint.



Savina Clinic opening at Malta International Airport in October 2013.

Planmeca delivered to Maltese Savina Clinic

Dental and Implantology Centre Savina Clinic recently opened a new high-end clinic at Malta International Airport. Planmeca Compact™ dental units were chosen to the clinic for their clean and professional design and excellent functionality.

Savina Clinic, originally established in Gozo, Malta in 1985, specializes in implantology, periodontics and dental prosthetics. Dr **Joseph Xuereb**, dental and implant surgeon and owner of the clinic wanted to open new premises offering prompt, high quality and affordable dentistry for both local and international customers.

He was looking for dental units that would fit well with the clinic's competent reputation. Dr Xuereb traveled to Helsinki, Finland to try out Planmeca's dental units – and was very impressed with their ergonomics, design and wheelchair-friendliness. "The units are really comfortable and not at all bulky. They are suitable with our interior design concept and they give a very professional image. Beautiful units!" Xuereb comments about the design of Planmeca's units.

Four **Planmeca Compact™** dental units were delivered to Savina Clinic which opened in October 2013 in SkyParks Business Centre at Malta Airport. The clinic consists of four treatment rooms but it is already expanding: two more rooms are prepared for Planmeca's dental units to arrive. A separate entrance and waiting room are offered for VIP clients and there are also facilities for disabled persons, including Planmeca's dental units which are fully adaptable to all wheelchairs. Clinic's central location makes it easily accessible from all parts of the island and proximity to the airport also attracts international customers.

In the clinic's opening ceremony **Joseph Muscat**, the Prime Minister of Malta, concluded that the new clinic sets the standard for Maltese dental care higher. According to him the clinic also works as a great example in promoting Malta in the field of medical and dental tourism.